

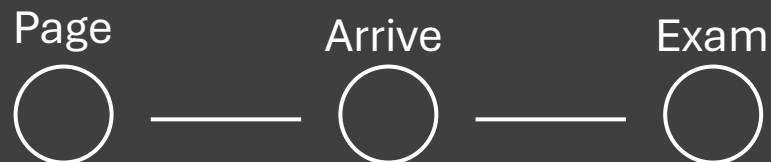
# Overdose Death Scene Investigation



The Medicolegal Death Investigator and the  
Investigation

# Paged to the Scene: 1045

- 22-year-old female
- Found in bedroom
- Not breathing not responding



# Assessing the Scene

“Sensory Experience”

- Safety
- Documentation
  - **Photography**
    - Law Enforcement vs. MEI photos
    - Comprehensive
      - Environment
      - Body
      - Identification documents
      - Evidence/potential evidence
    - More is better than less
  - Narrative Report
- Sketching
- Statements/Heard
- Smells
- Sights
- Touch/Handled
- Visualization of Scene
  - What ***is there*** that should **NOT** be there
  - What is ***not there*** that **should be** there
  - What ***is there*** that ***should be*** there but is **NOT** in a proper place

# Arrival on Scene: 1047

## Personnel Present:

First Responders

Law Enforcement

EMS

Fire Department

Decedent's Roommate

Lauren

Decedent's Father

Charles but goes by Charlie

## Goals:

Identification

Next of Kin

Cause | Manner of Death determination

Timeline: LKA | TOD

Decedent's: Medical | Social | Psychological history

Evidence: Identification | Management

Identify any changes made to the scene

Page



Arrive



Exam



# Scene Investigation: 1100

Evidence of:

Naloxone

Needles

Straws

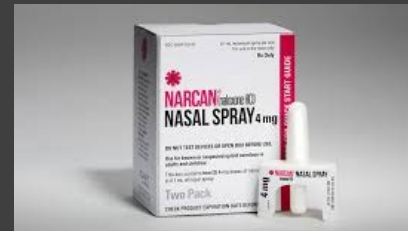Burnt pipes

Lighters

Rolled up bills

Tourniquet

Other evidence



Page



Arrive



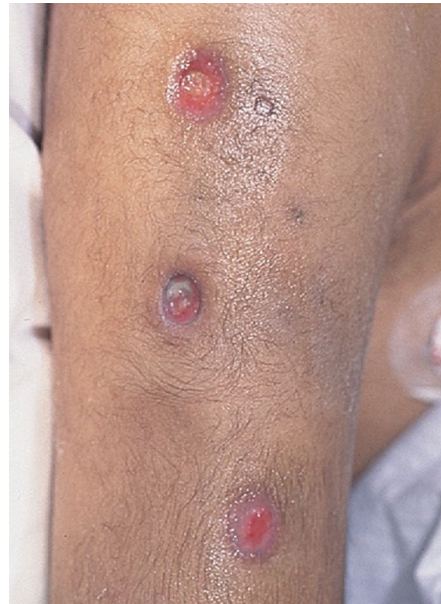
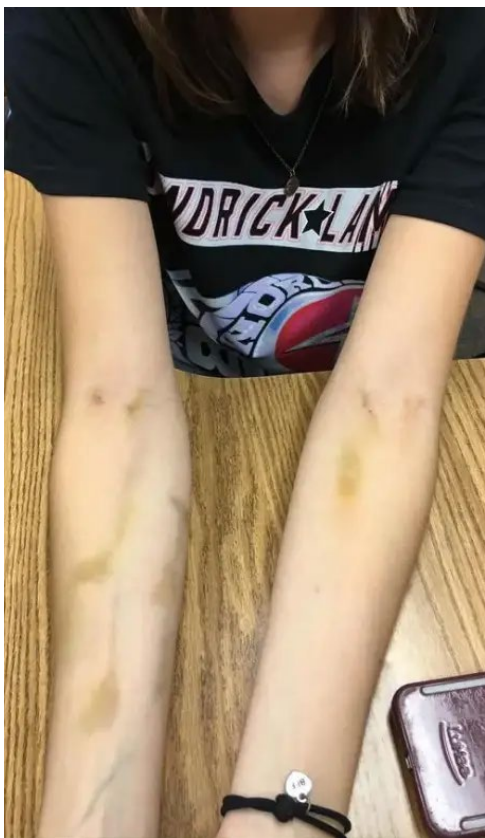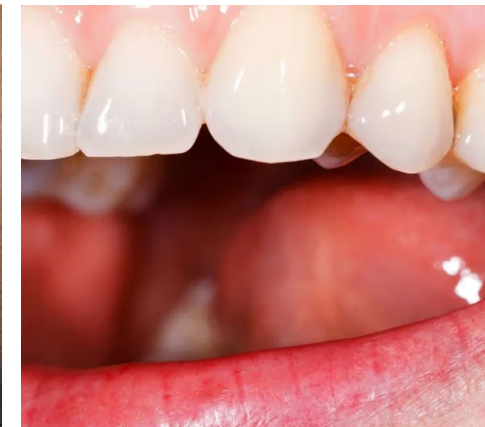Exam



# **WARNING**

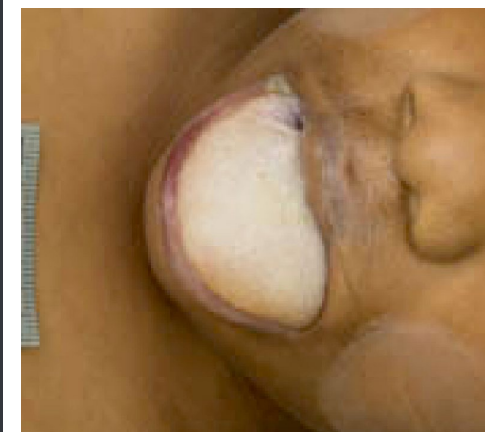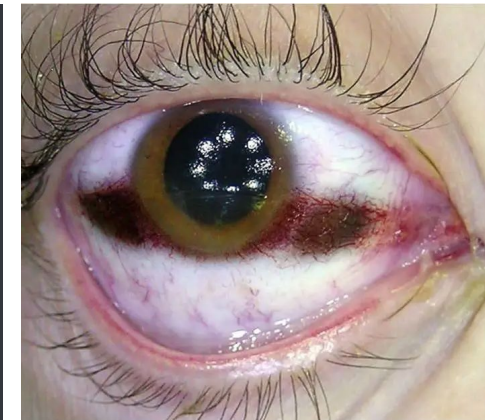**This gallery contains graphic  
images that some viewers  
may find disturbing**

# Exam of the Decedent: 1115

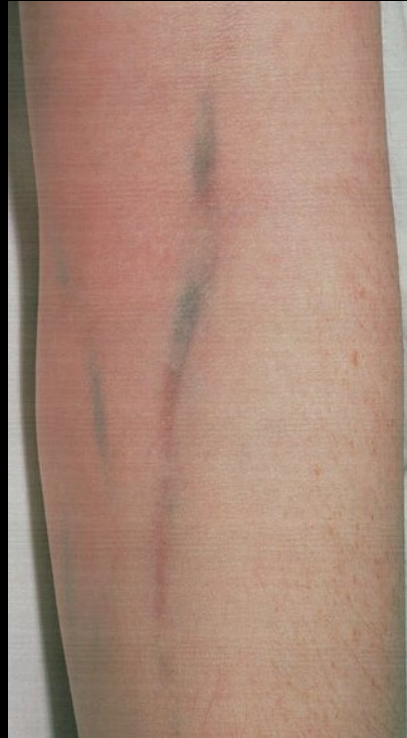
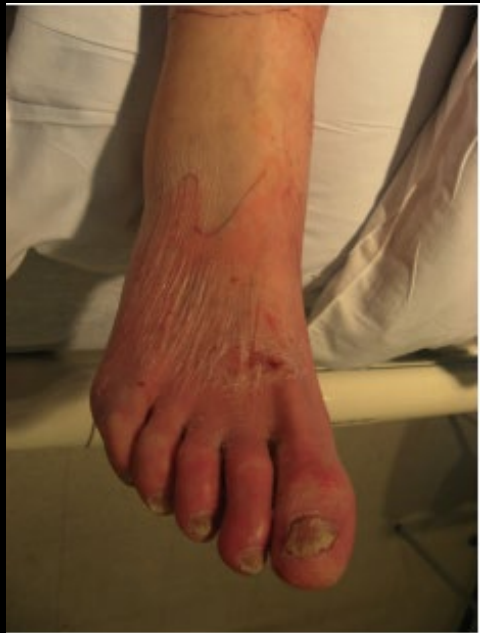
## Evidence:

- Foam Cone
- Nontherapeutic Needle Marks
- Rigor/Algor/Livor/Pallor Mortis
- Cutis Anserina
- Tache Noir
- Vomitus
- Incontinence
- Scars



# Signs of Chronic Opioid Use (Heroin)



Aged 22 years



Aged 23 years



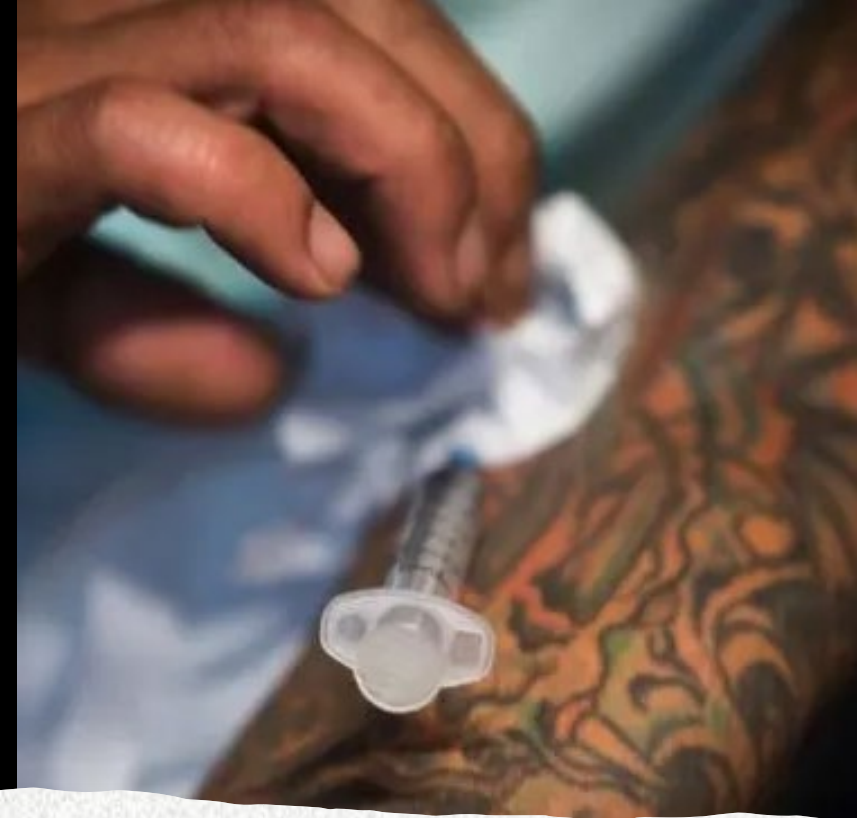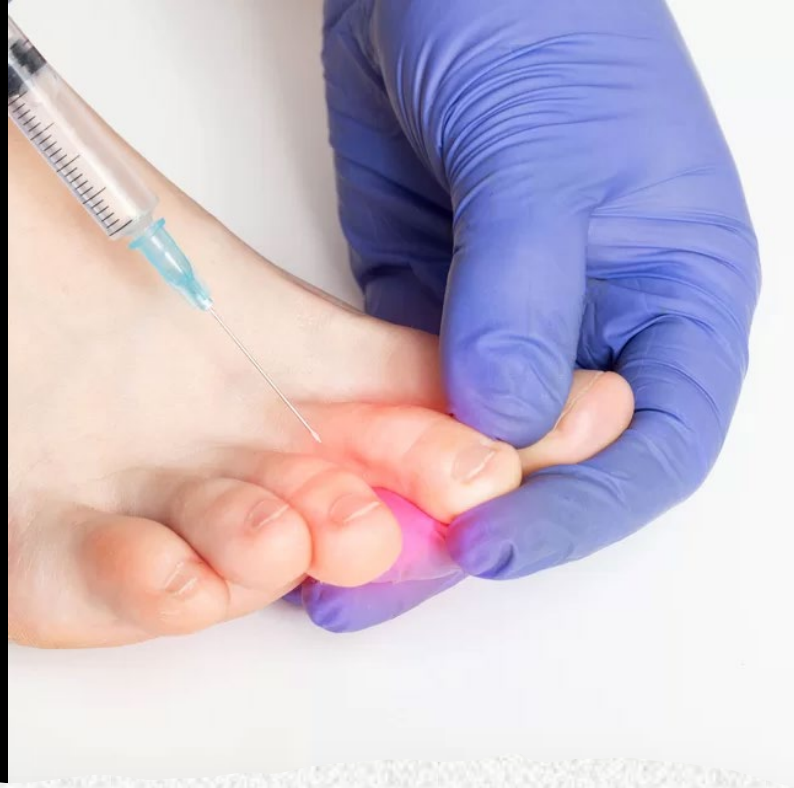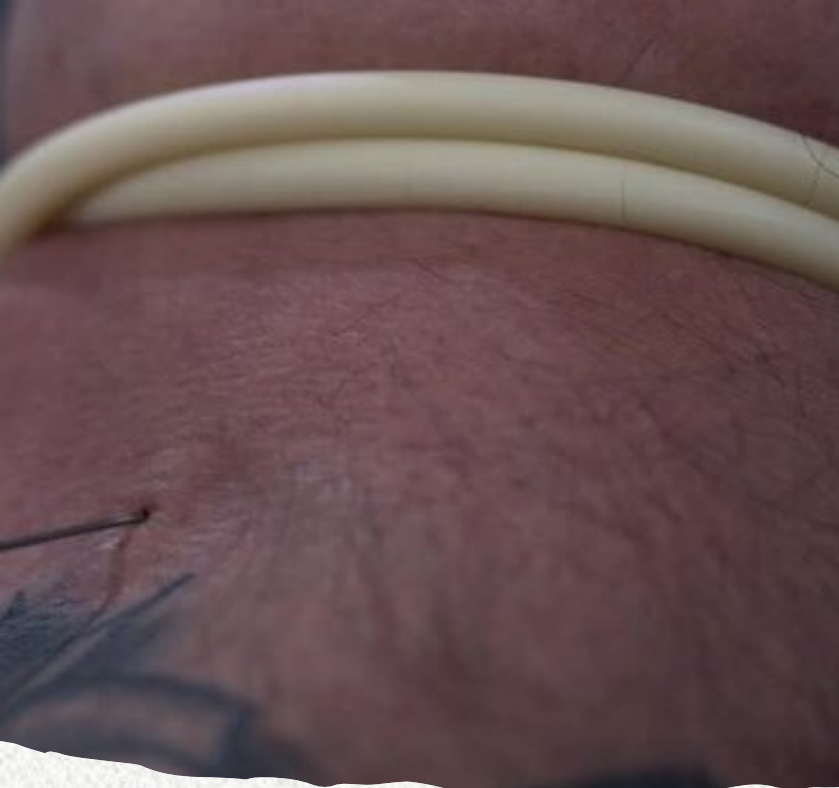Aged 29 years



Aged 31 years

[https://www.physio-pedia.com/Cellulitis#/media/File:Classic\\_celulitis.PNG](https://www.physio-pedia.com/Cellulitis#/media/File:Classic_celulitis.PNG)

<https://modernrecoveryservices.com/conditions/addiction/substances/opioids/heroin/before-and-after-addiction/>



## Finding Opioid Injection Sites

- Tattoos
- Foot/Toes
- Groin (penis)
- Axillae (armpit)
- Tongue
- Neck
- Inner thigh
- Wrist/Fingers

# Closing the Scene: 1130

## Considerations:

- Provide Charlie the information for next steps
- Allow time for questions
- Involve the Victim's Services Unit
- Cultural Considerations

## Considerations if Next of Kin is not on scene:

- Ensure the correct next of kin is identified
- Notify in person
- Provide a synopsis of circumstances
- Provide information about location of the decedent's body
- Provide contact information for the MEO
- Approach to notification is care, compassion, professionalism, and accuracy

Page



Arrive



Exam



# References

DINIS-OLIVEIRA, R. J.; SANTOS, A.; MAGALHÃES, T. “Foam Cone” exuding from the mouth and nostrils following heroin overdose. **Toxicology Mechanisms & Methods**, [s. l.], v. 22, n. 2, p. 159–160, 2012. DOI 10.3109/15376516.2011.610388. Disponível em: <https://research-ebSCO-com.cmich.idm.oclc.org/linkprocessor/plink?id=5369fc6d-827e-3ac8-b490-a47ecbf1b062>. Acesso em: 15 abr. 2025.

Justice Department. (2004, December 31). Parafernalia De Drogas. [Government]. Justice Department. <https://www.govinfo.gov/app/details/GOVPUB-J-PURL-gpo11465>

Wikipedia Accessed 05/27/2025  
[https://en.wikipedia.org/wiki/Drug\\_precursors](https://en.wikipedia.org/wiki/Drug_precursors)